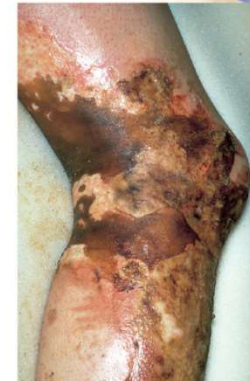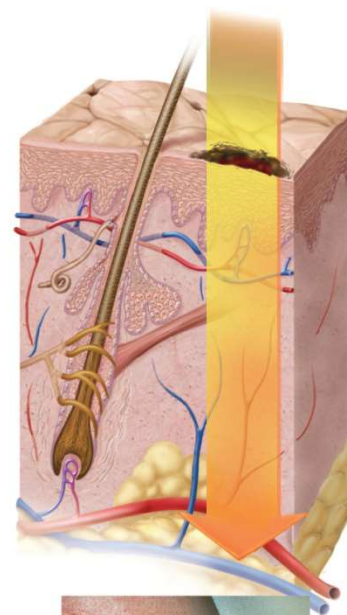
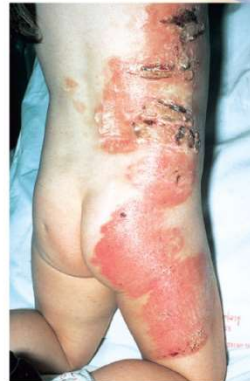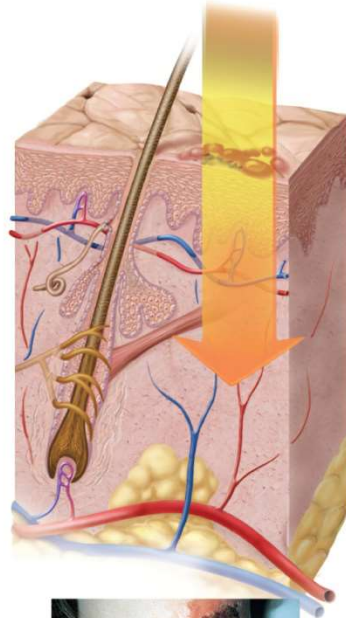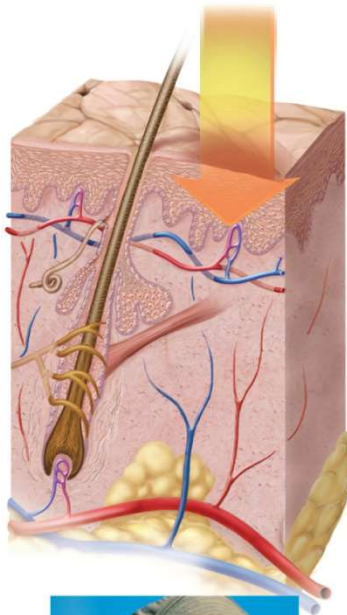


Chapter 5.5

Burns



Burns

- Leading cause of accidental death
 - fires, kitchen spills, sunlight, ionizing radiation, strong acids or bases, or electrical shock
 - deaths result primarily from fluid loss, infection and toxic effects of **eschar** (burned, dead tissue)
 - **debridement** – the removal of eschar

Burns – Three Degrees

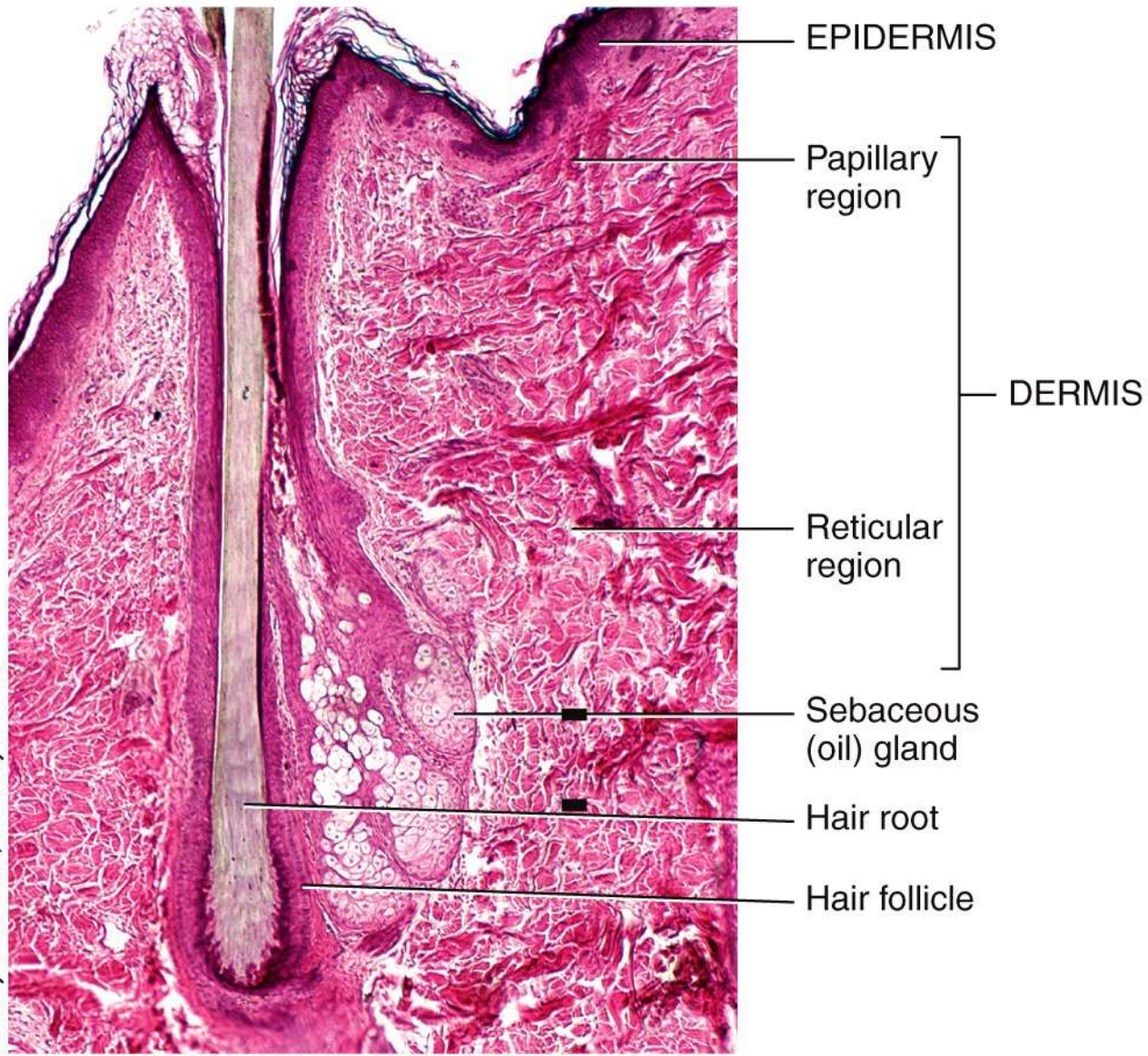
- Classified according to the depth of tissue involvement /// first degree – second degree – third degree burns
 - **first-degree burns** (**partial thickness burn**) - involve only the epidermis
 - marked by redness, slight edema, and pain
 - heal in a few days
 - most sunburns are first degree burns
 - **second-degree burns** (**partial thickness burn**) - involve the epidermis and part of the dermis
 - leaves part of the dermis intact
 - red, tan, or white
 - two weeks to several months to heal and may leave scars
 - blistered and very painful

Burns – Three Degrees

– **third-degree burn** (full thickness burn)

- the epidermis and all of the dermis, and often some deeper tissues (muscles or bones) are destroyed
- often require skin grafts
- needs fluid replacement and infection control
- no pain / pain receptors gone (nociceptors)!

Courtesy Michael Ross, University of Florida



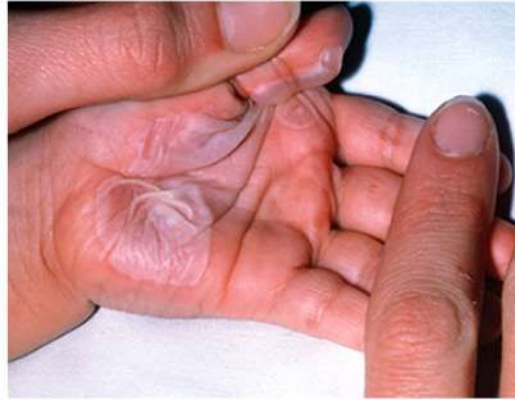LM 60x

(b) Sectional view of skin

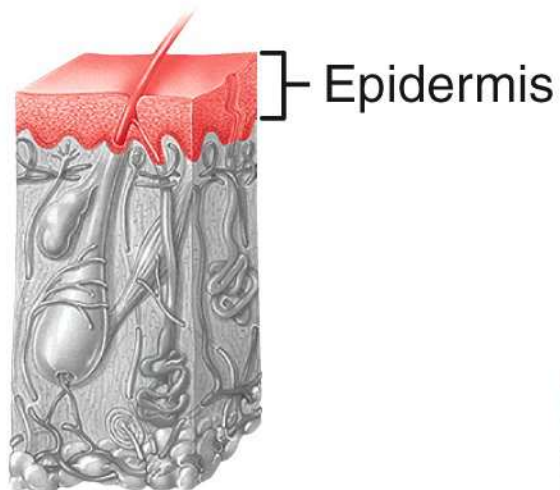
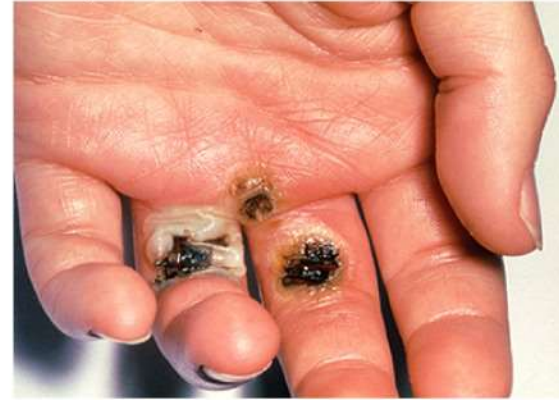Sheila Terry/Science Photo Library/
Photo Researchers, Inc.



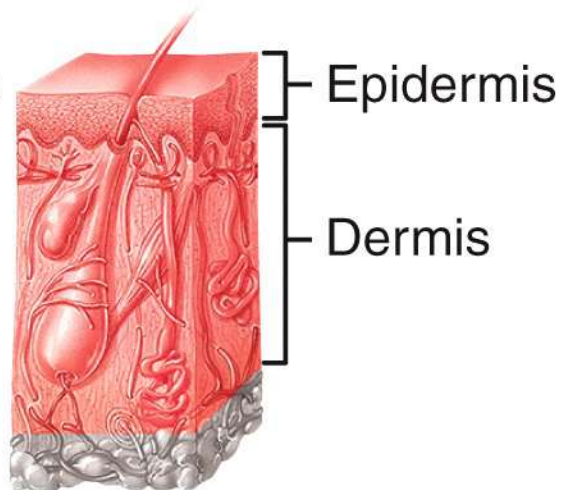
St. Stephen's Hospital/Science Photo
Library/Photo Researchers, Inc.



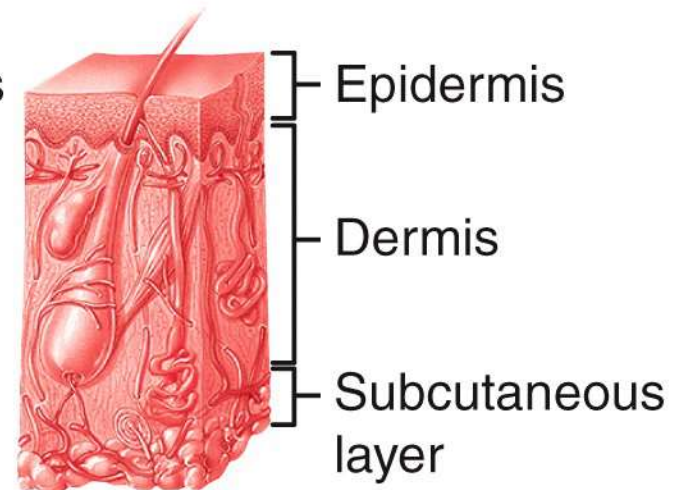
St. Stephen's Hospital/Science Photo
Library/Photo Researchers, Inc.



(a) First-degree burn
(sunburn)

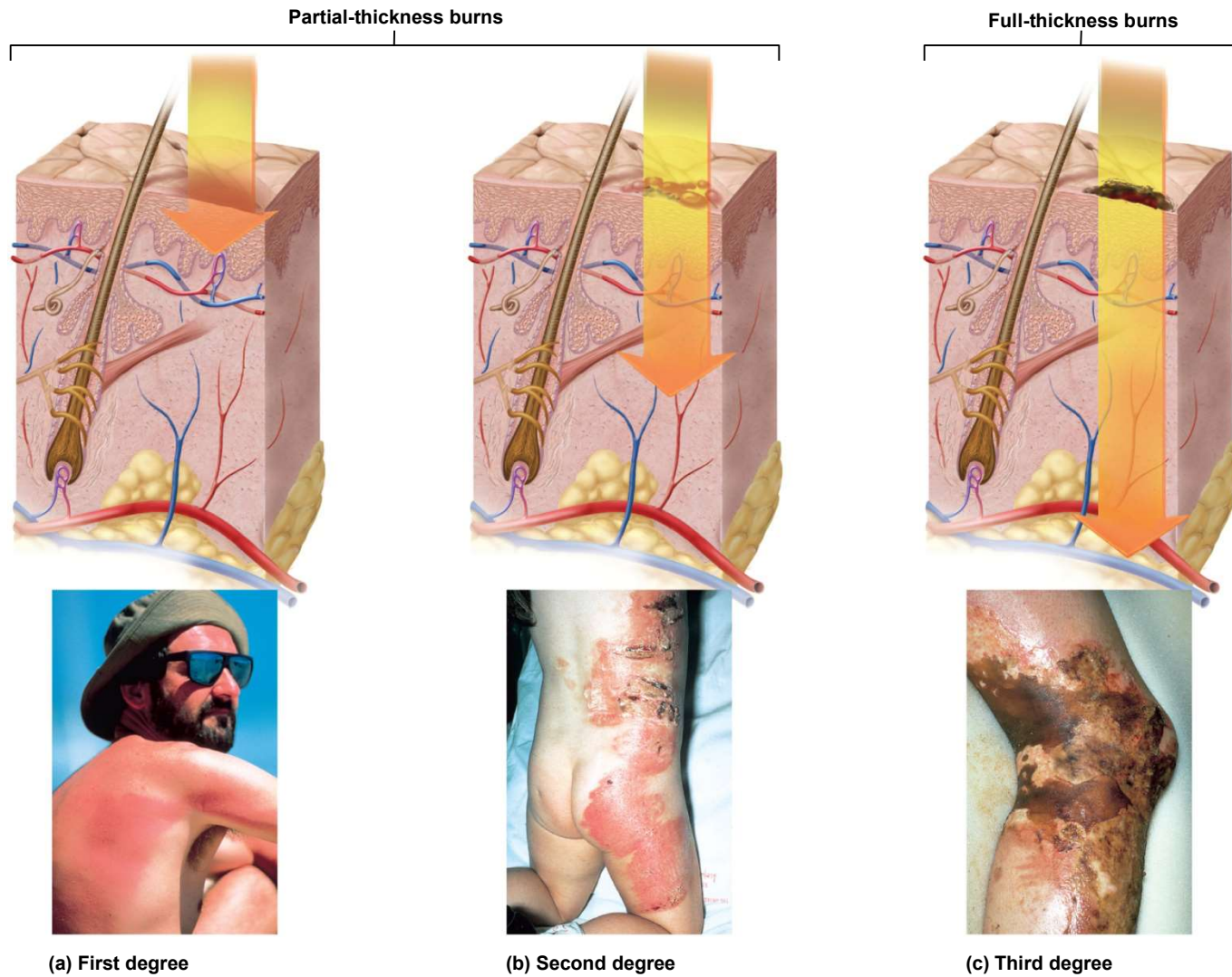


(b) Second-degree burn
(note the blisters in
the photograph)



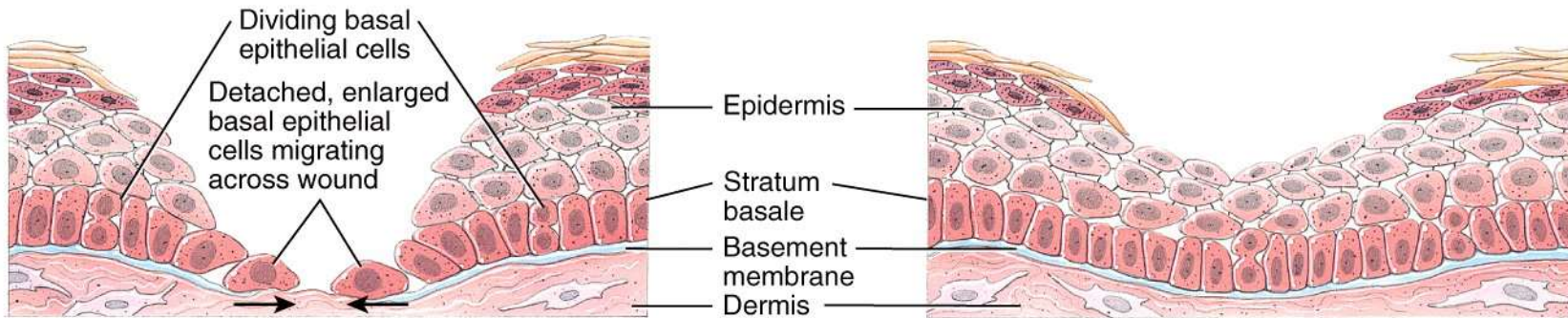
(c) Third-degree burn

Degrees of Burn Injuries



Skin Grafts and Artificial Skin

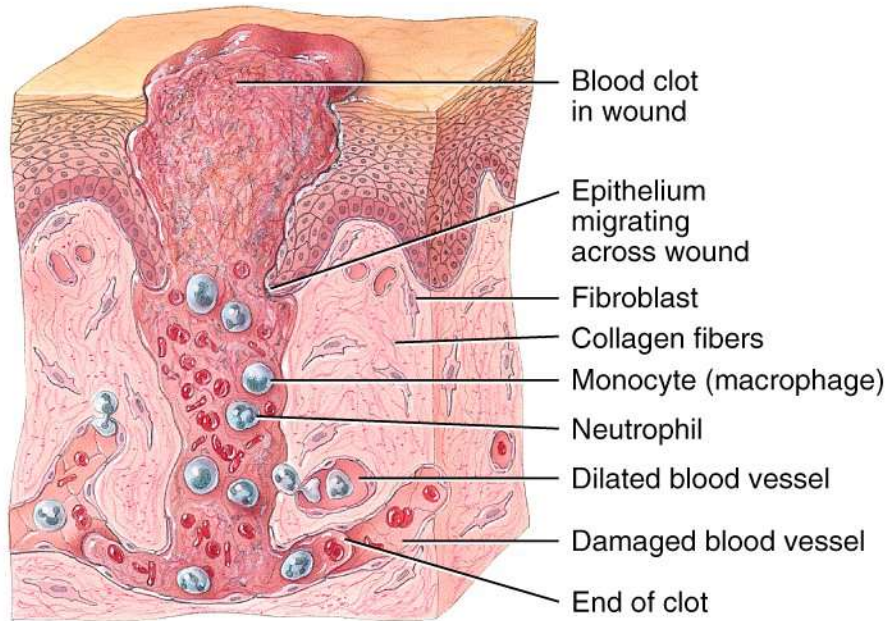
- third-degree burns require skin grafts
- graft options
 - **autograft** - tissue taken from another location on the same person's body // **split-skin graft** – taking epidermis and part of the dermis from an undamaged area such as the thigh or buttocks and grafting it into the burned area
 - **isograft** - skin from identical twin
- temporary grafts (immune system rejection)
 - **homograft (allograft)** -- from unrelated person
 - **heterograft (xenograft)** -- from another species
 - amnion from afterbirth
 - artificial skin from silicone and collagen



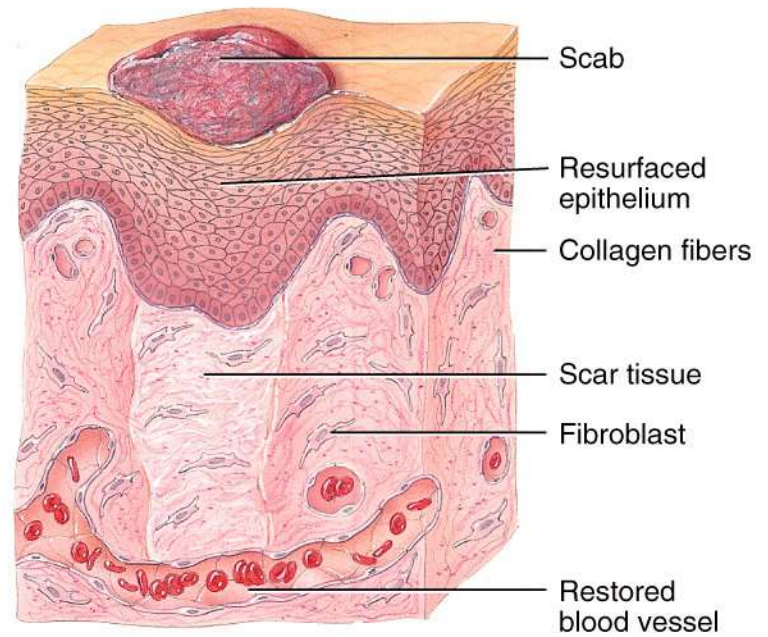
(a) Division of stratum basale cells and migration across wound

(b) Thickening of epidermis

Epidermal wound healing

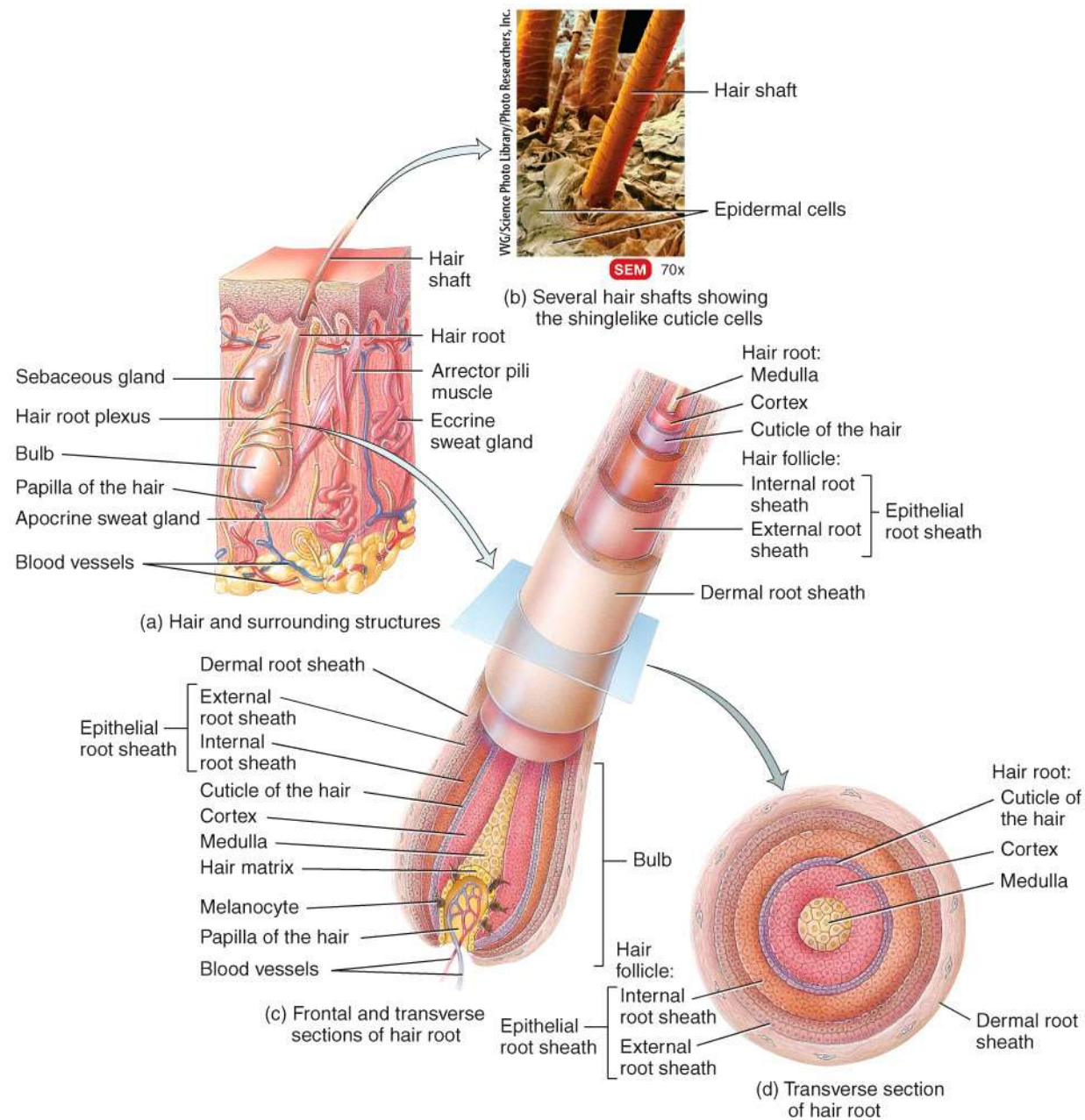


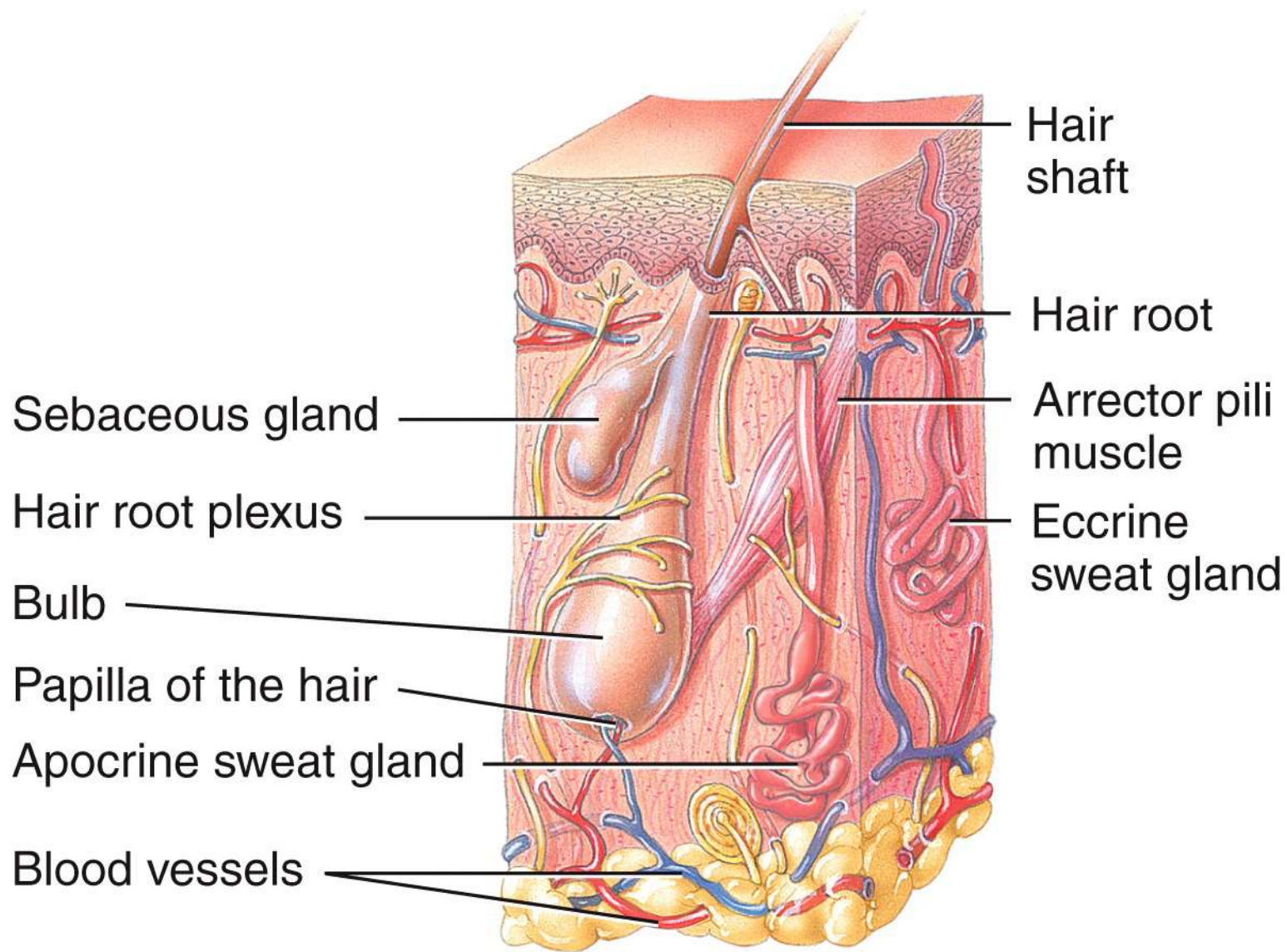
(c) Inflammatory phase



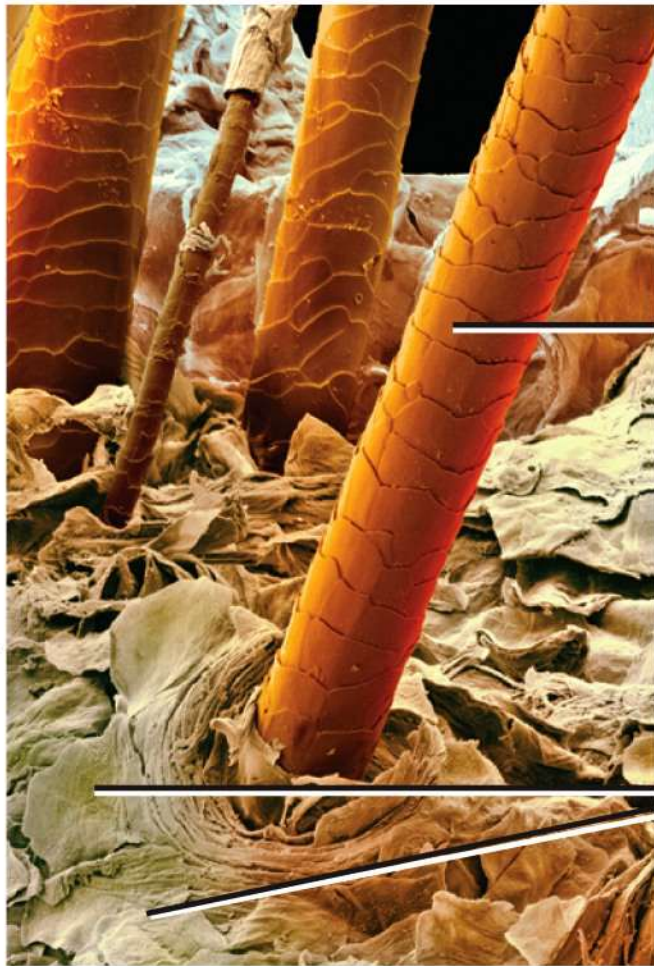(d) Maturation phase

Deep wound healing





(a) Hair and surrounding structures



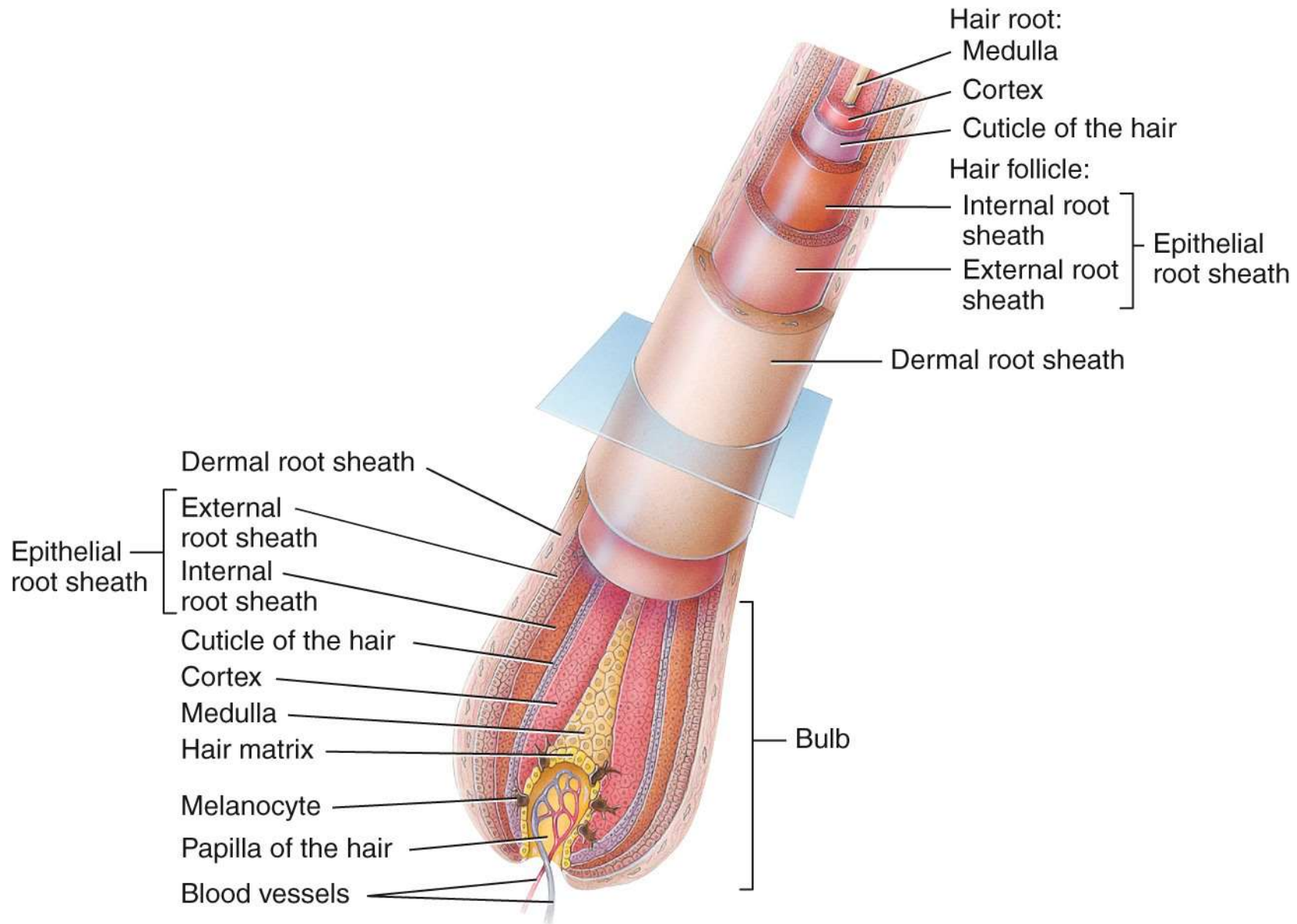
Hair shaft

Epidermal cells

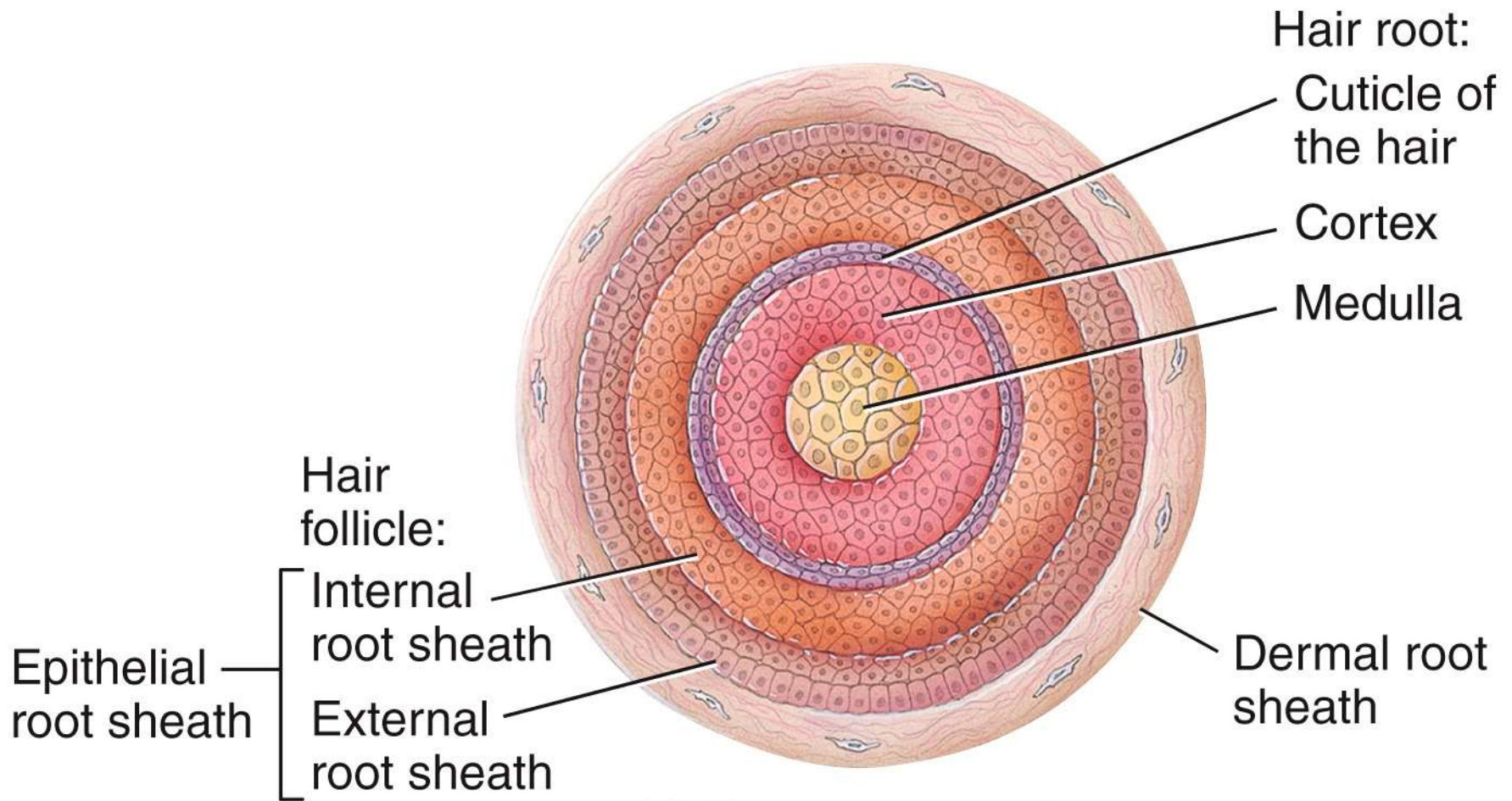
SEM

70x

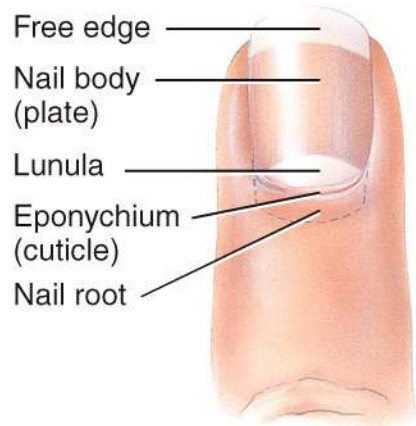
(b) Several hair shafts showing
the shinglelike cuticle cells



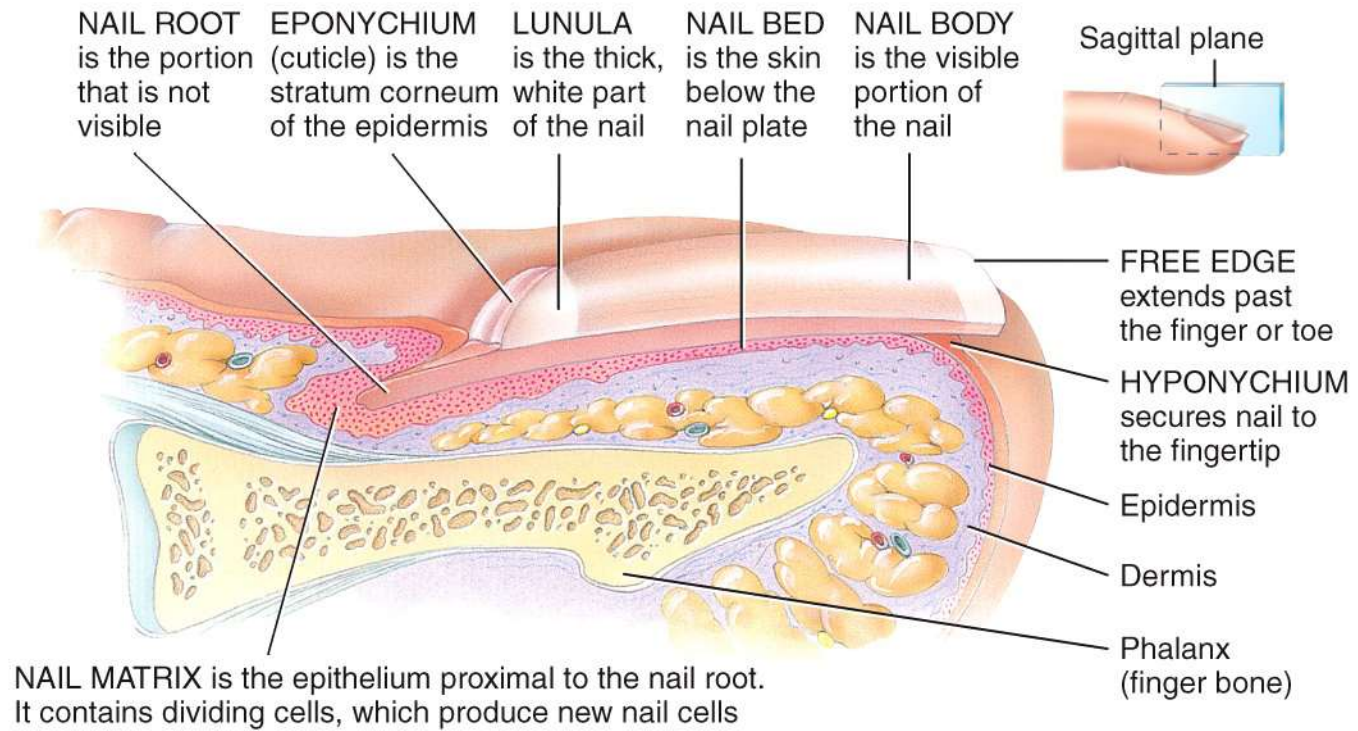
(c) Frontal and transverse sections of hair root



(d) Transverse section of hair root



(a) Dorsal view



(b) Sagittal section showing internal detail

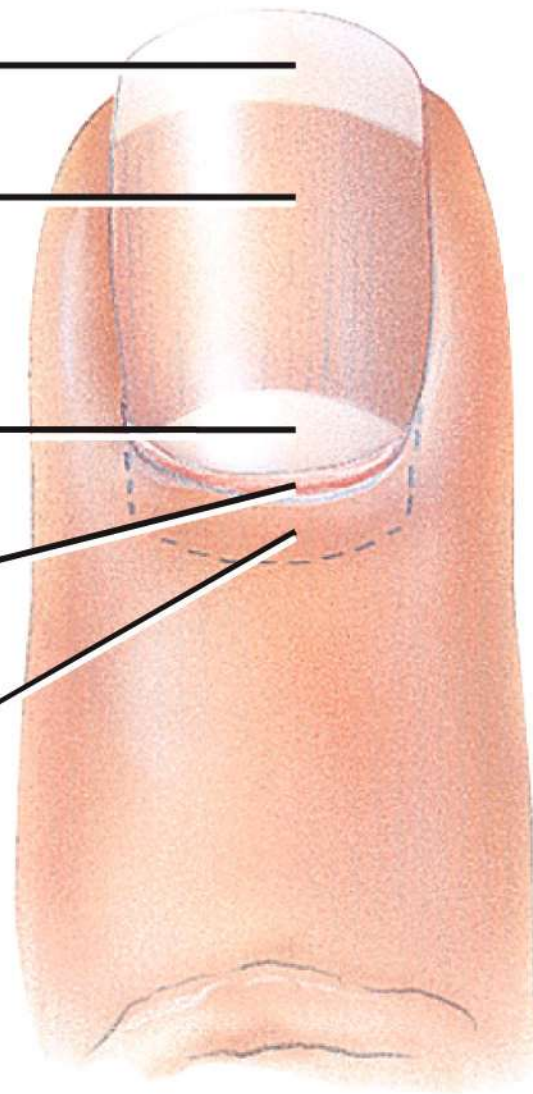
Free edge

Nail body
(plate)

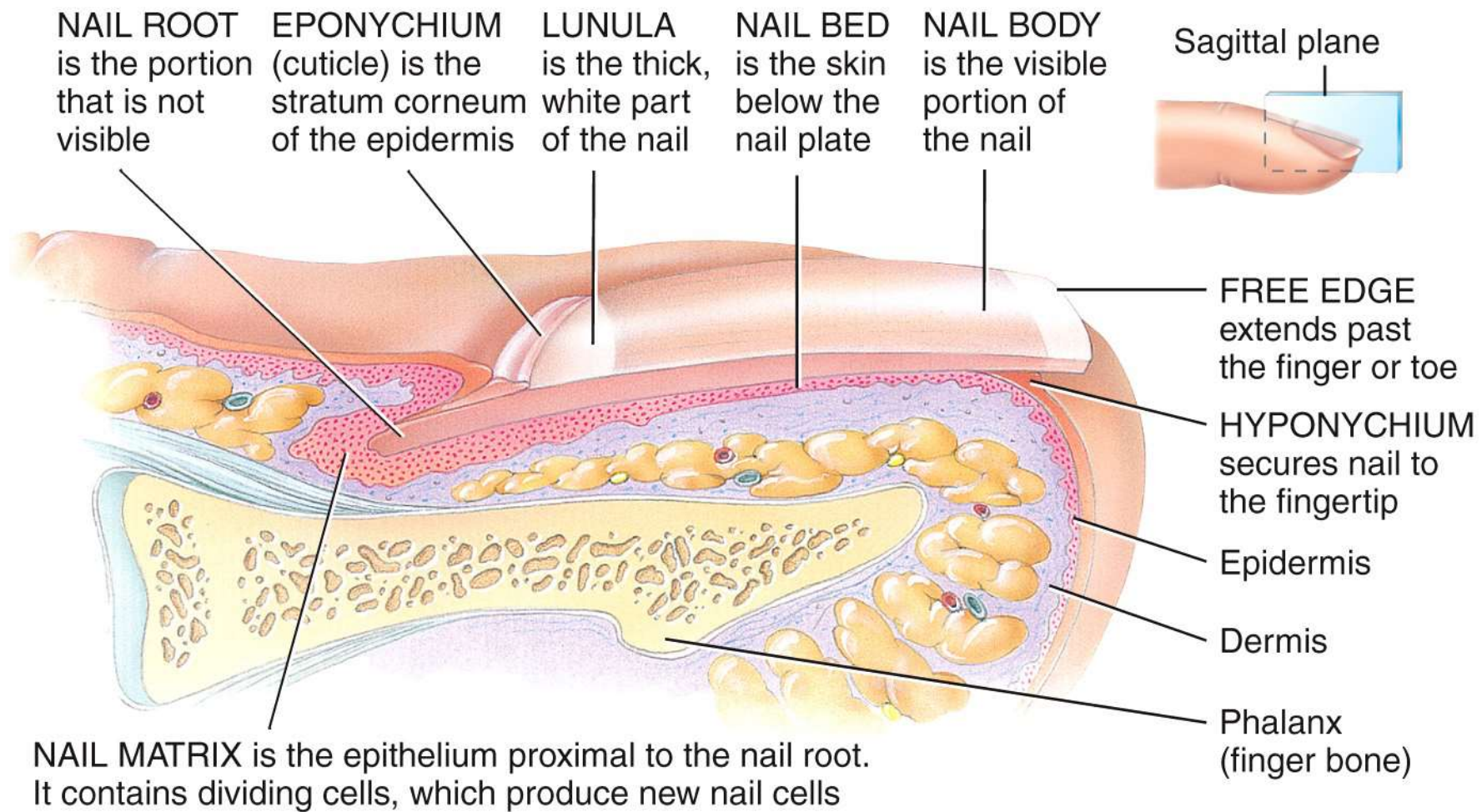
Lunula

Eponychium
(cuticle)

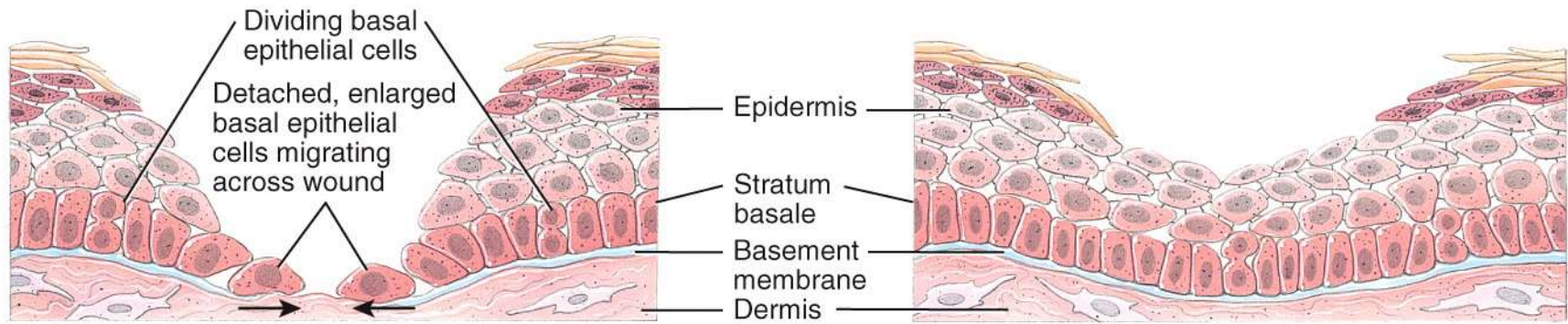
Nail root



(a) Dorsal view



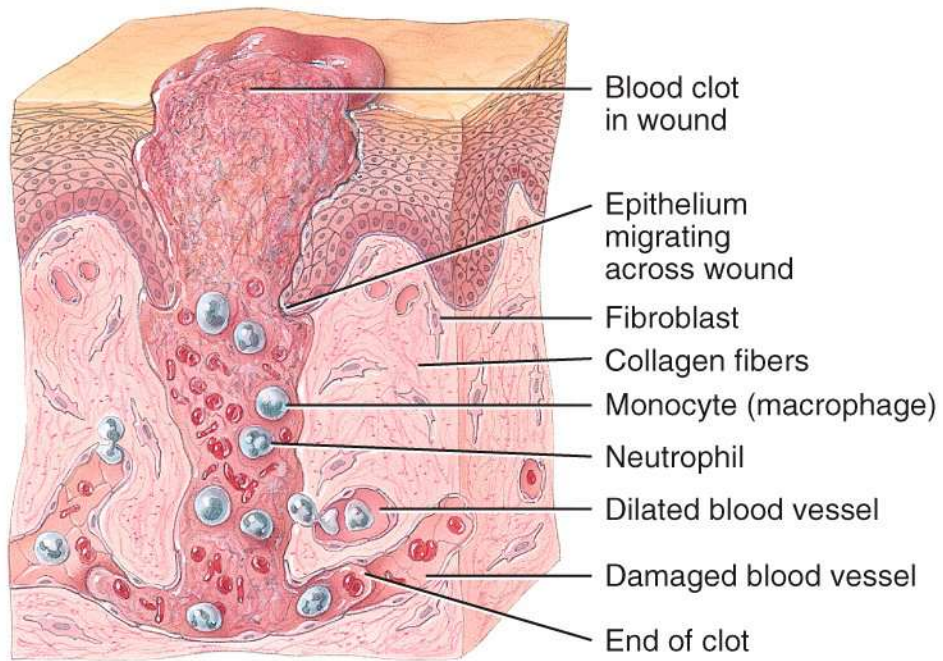
(b) Sagittal section showing internal detail



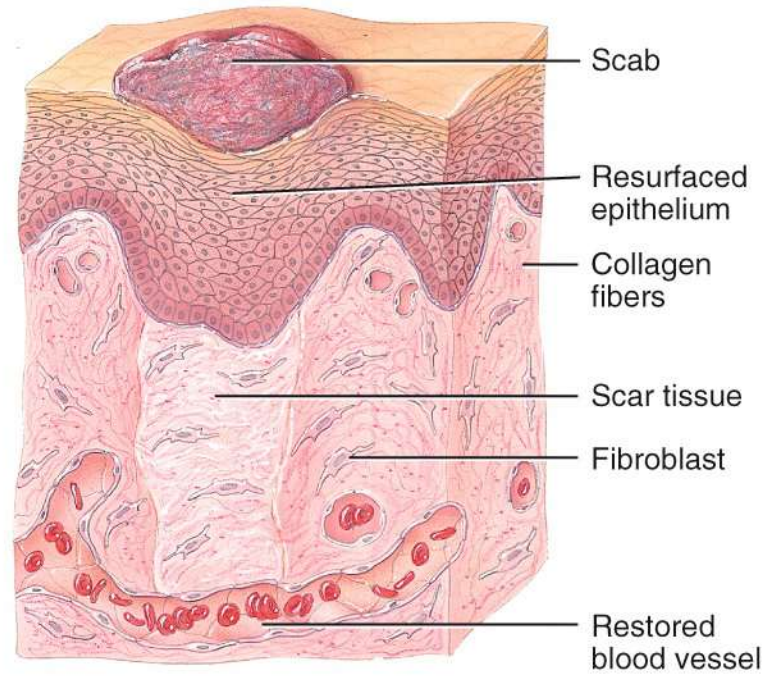
(a) Division of stratum basale cells and migration across wound

(b) Thickening of epidermis

Epidermal wound healing

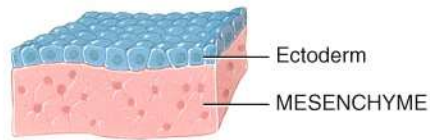


(c) Inflammatory phase

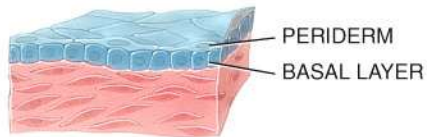


(d) Maturation phase

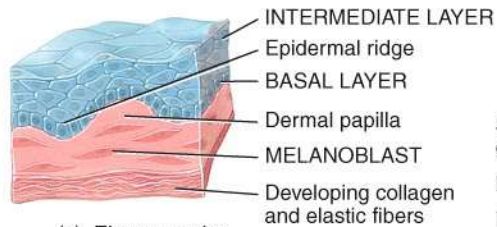
Deep wound healing



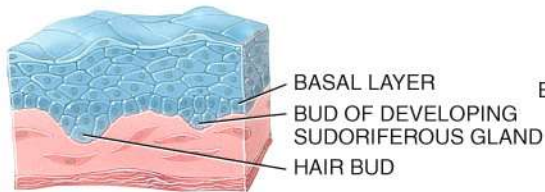
(a) Fourth week



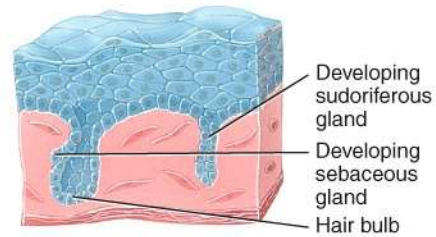
(b) Seventh week



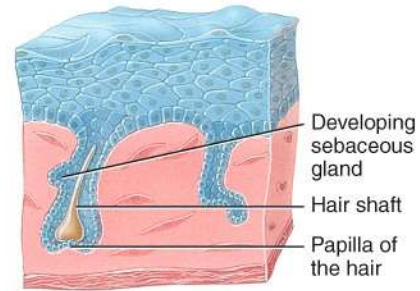
(c) Eleven weeks



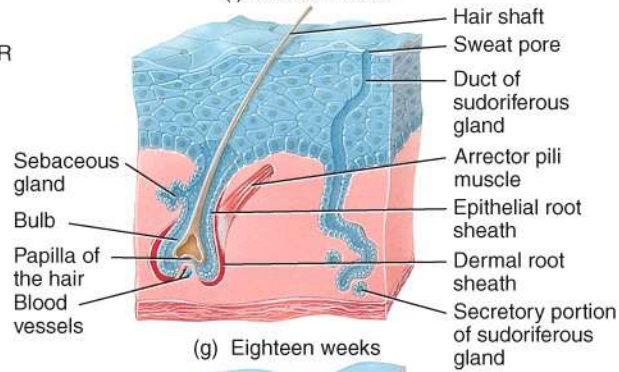
(d) Twelve weeks



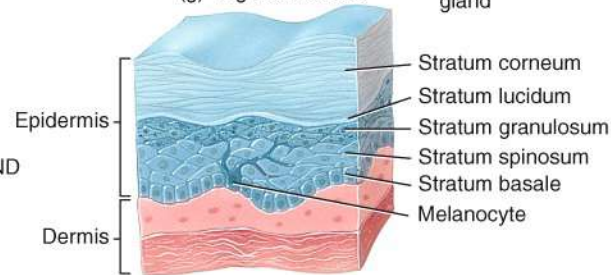
(e) Fourteen weeks



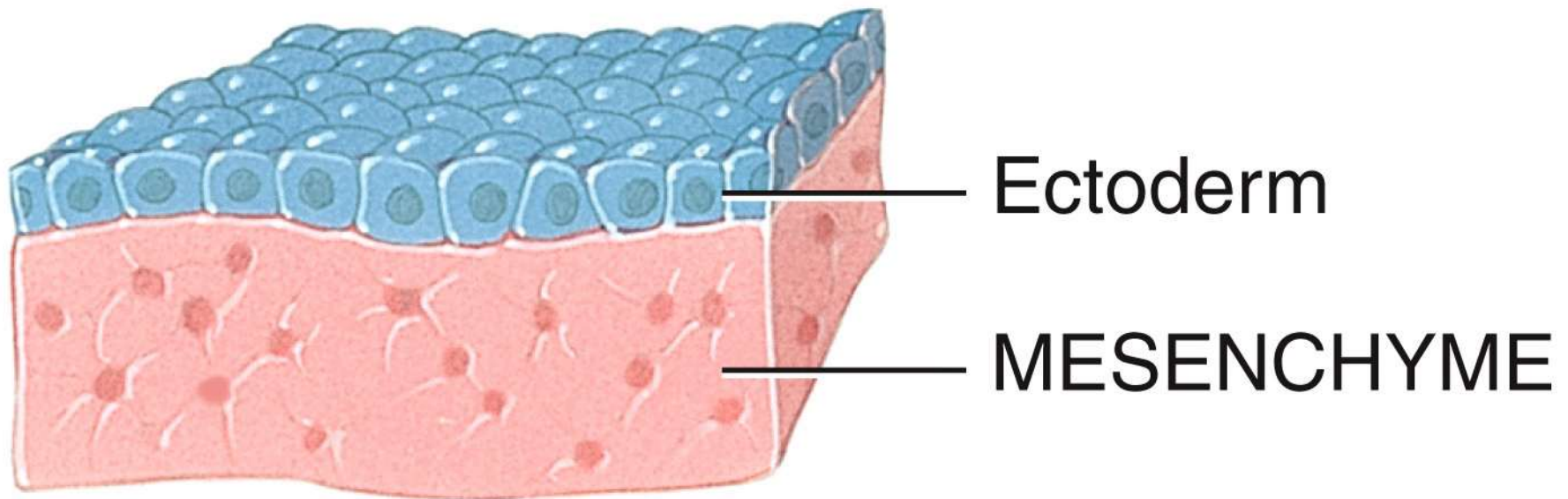
(f) Sixteen weeks



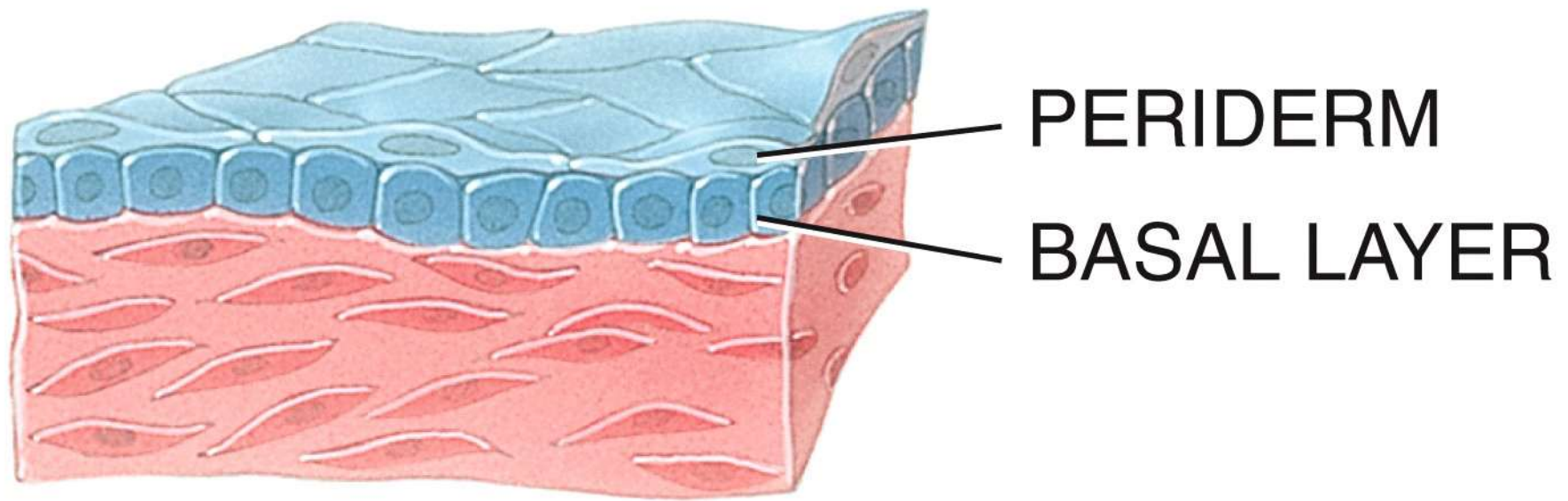
(g) Eighteen weeks



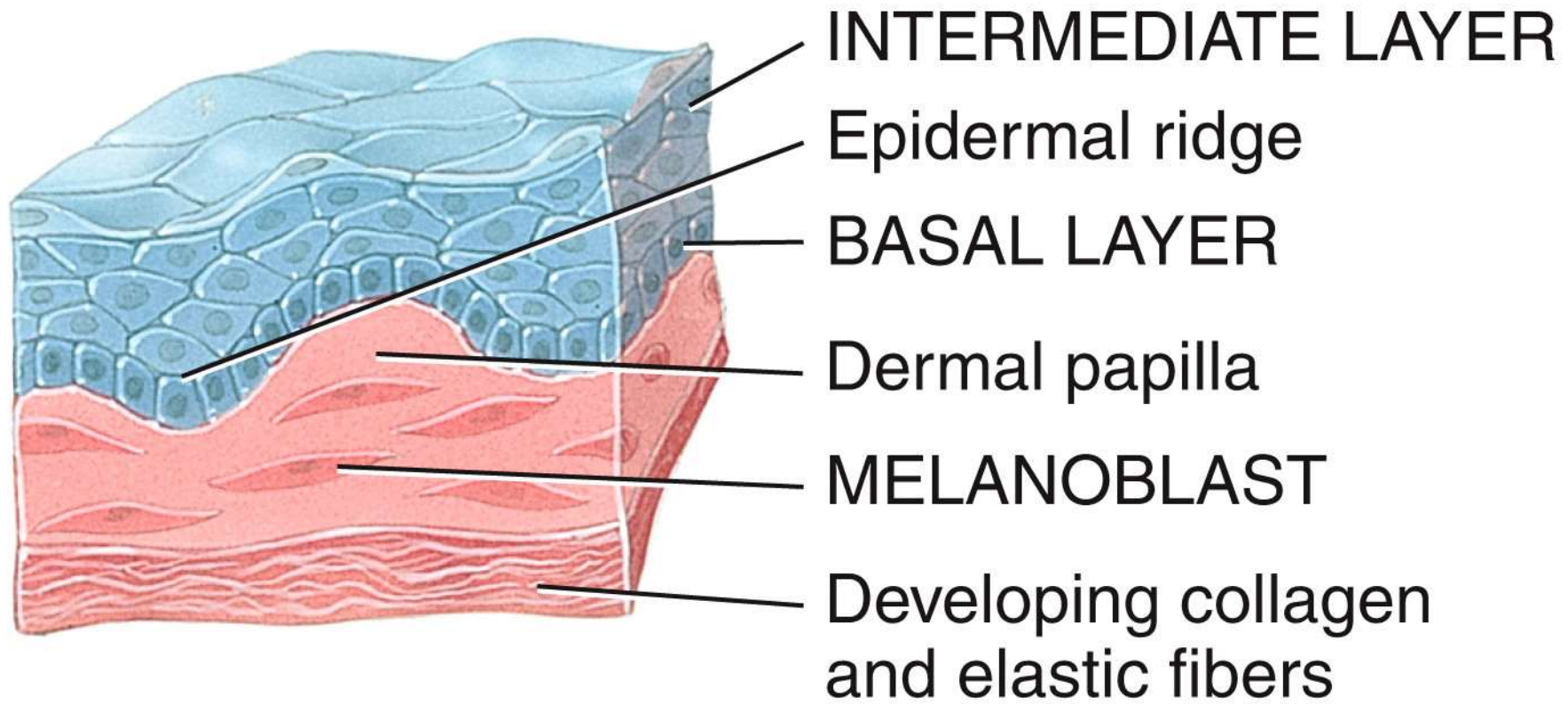
(h) At birth



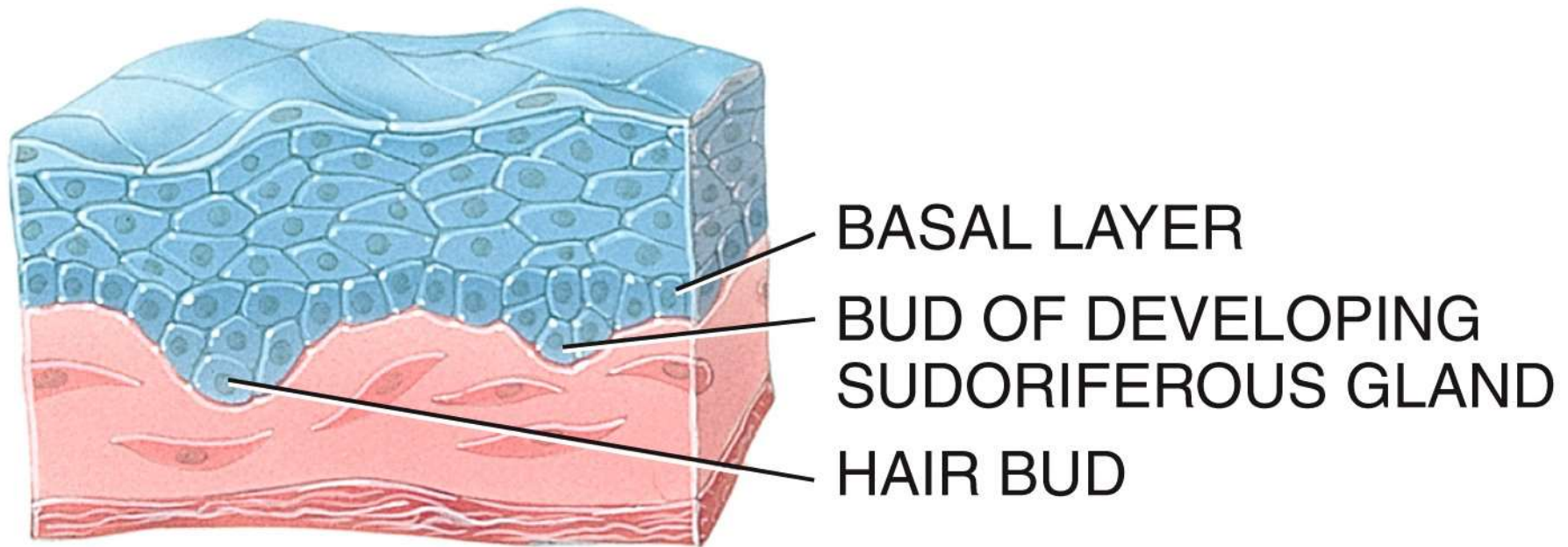
(a) Fourth week



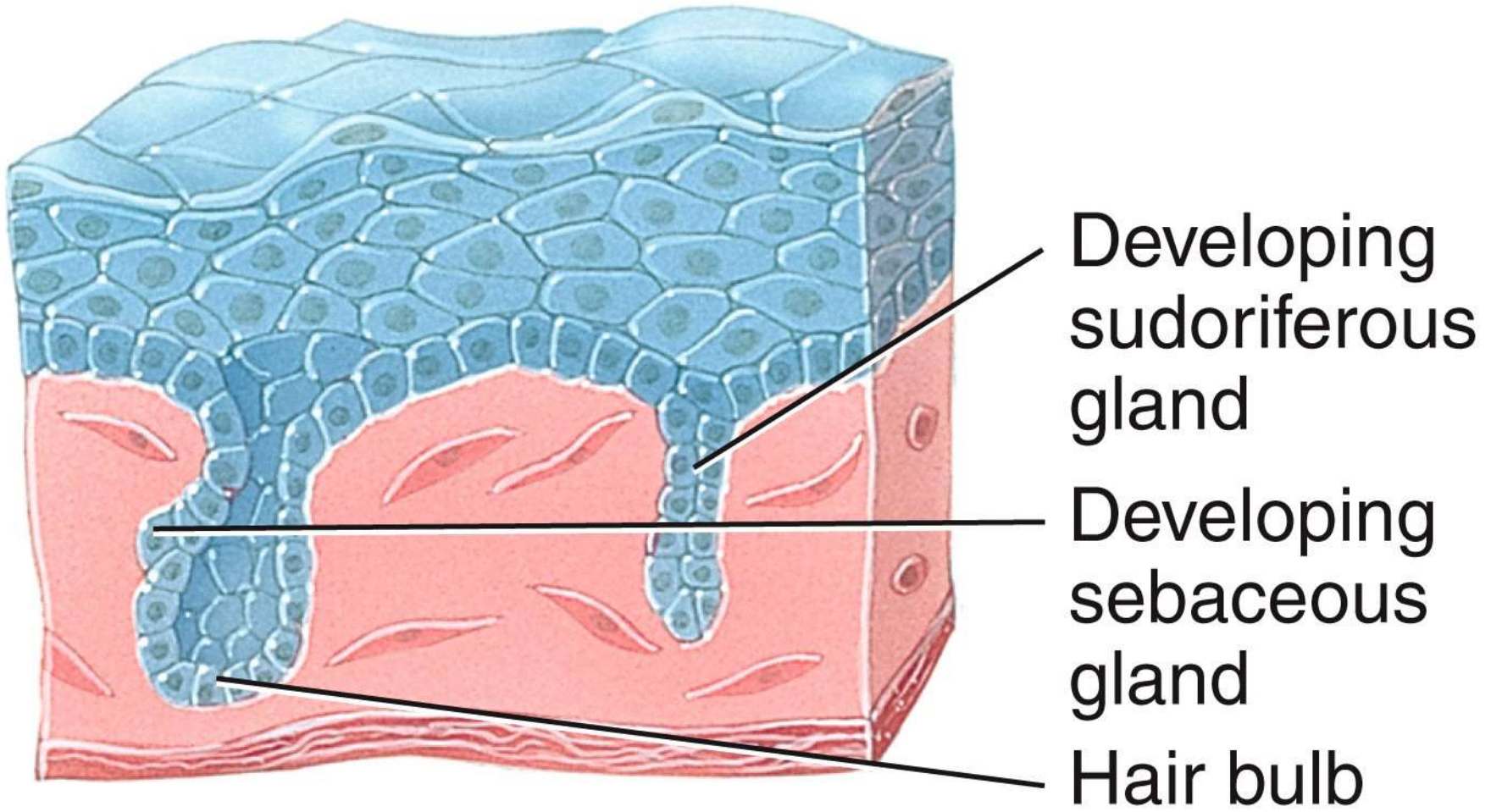
(b) Seventh week



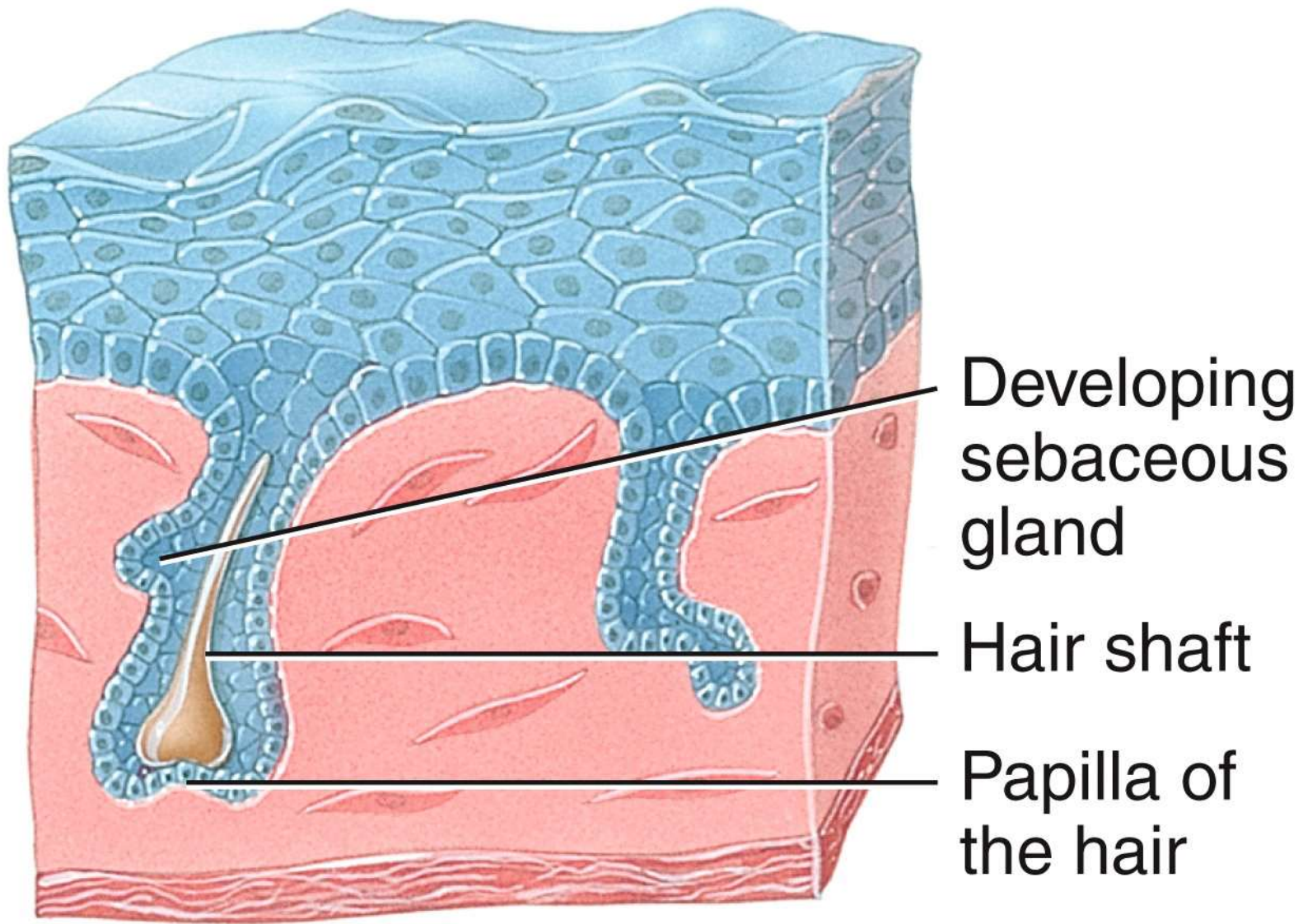
(c) Eleven weeks



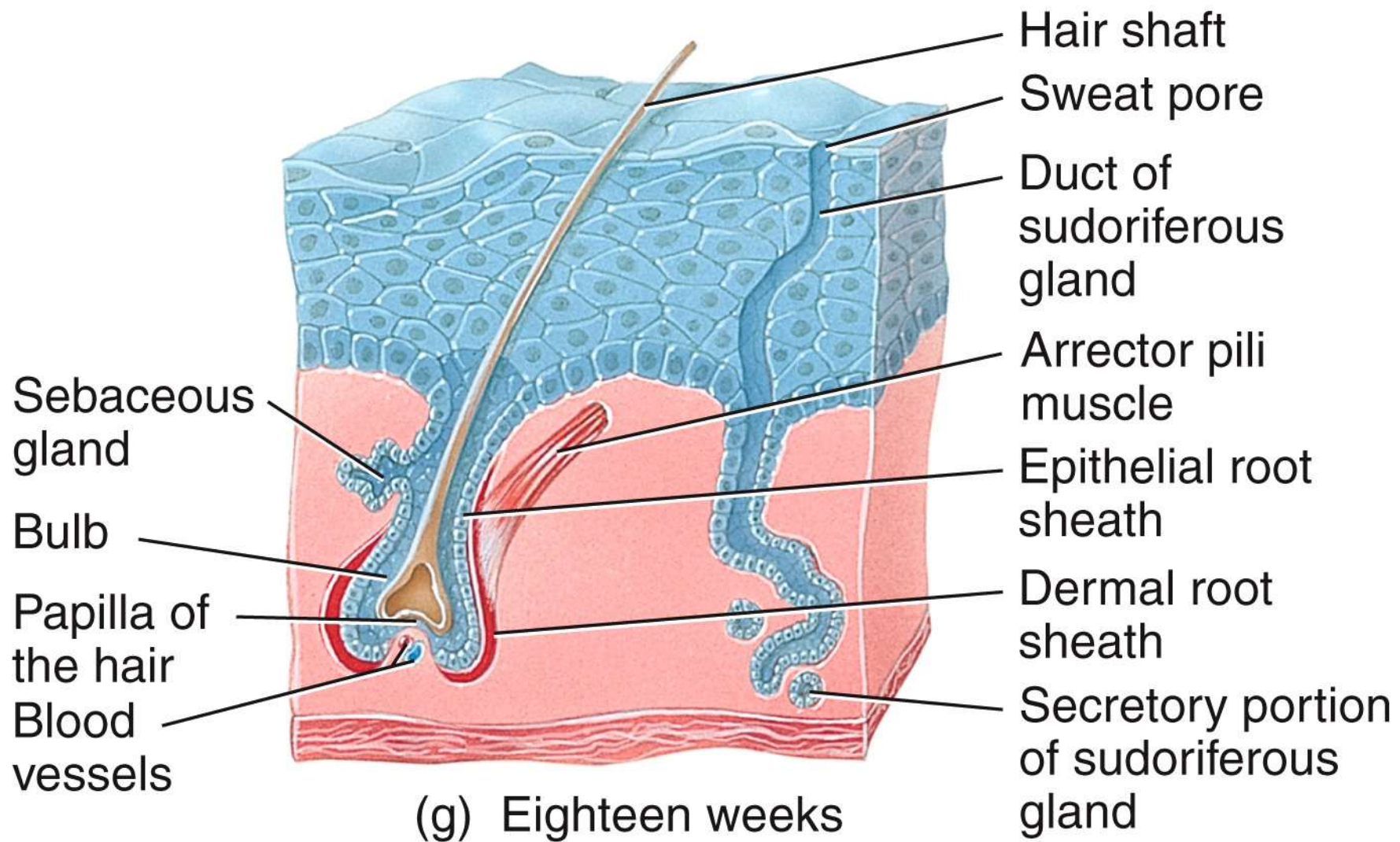
(d) Twelve weeks

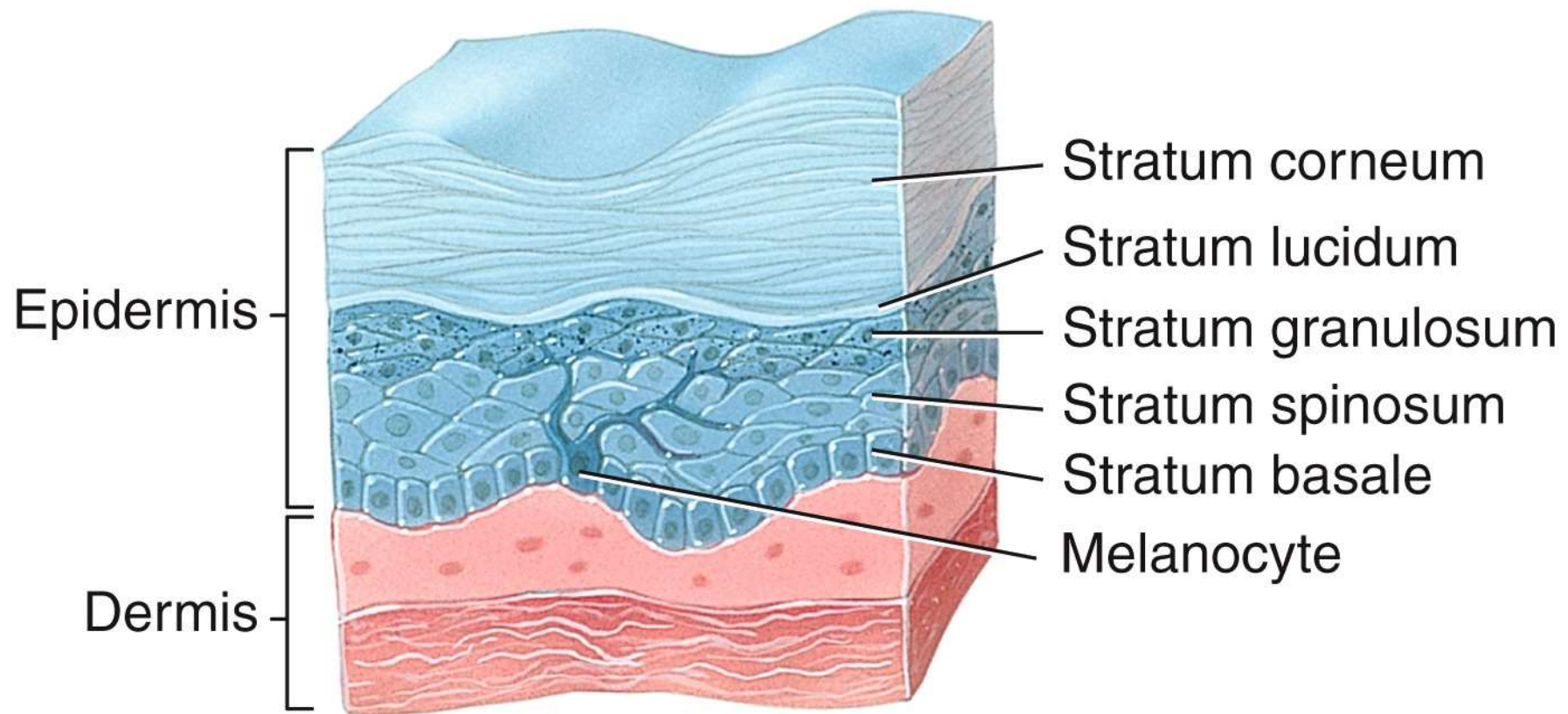


(e) Fourteen weeks

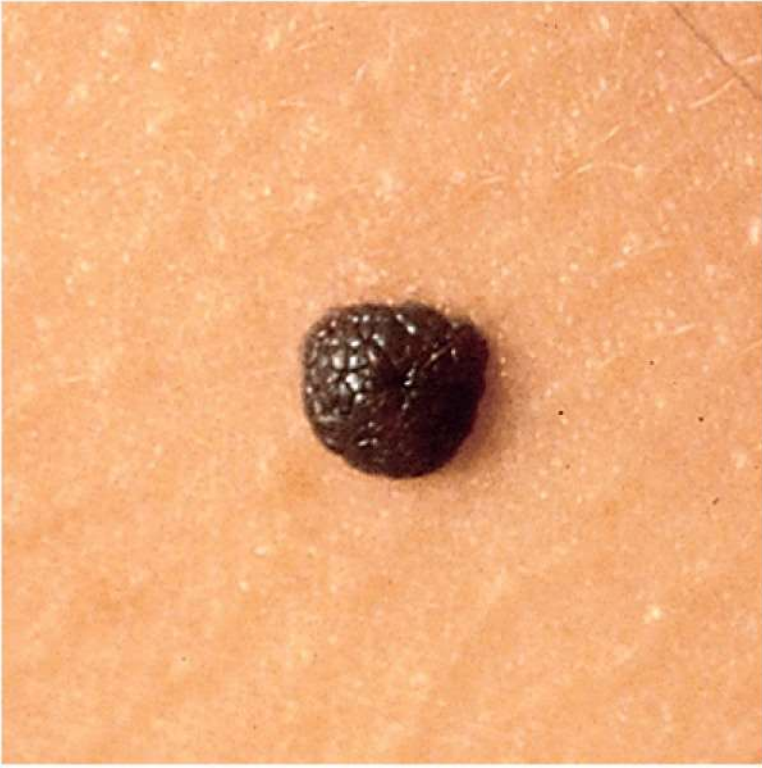

(f) Sixteen weeks

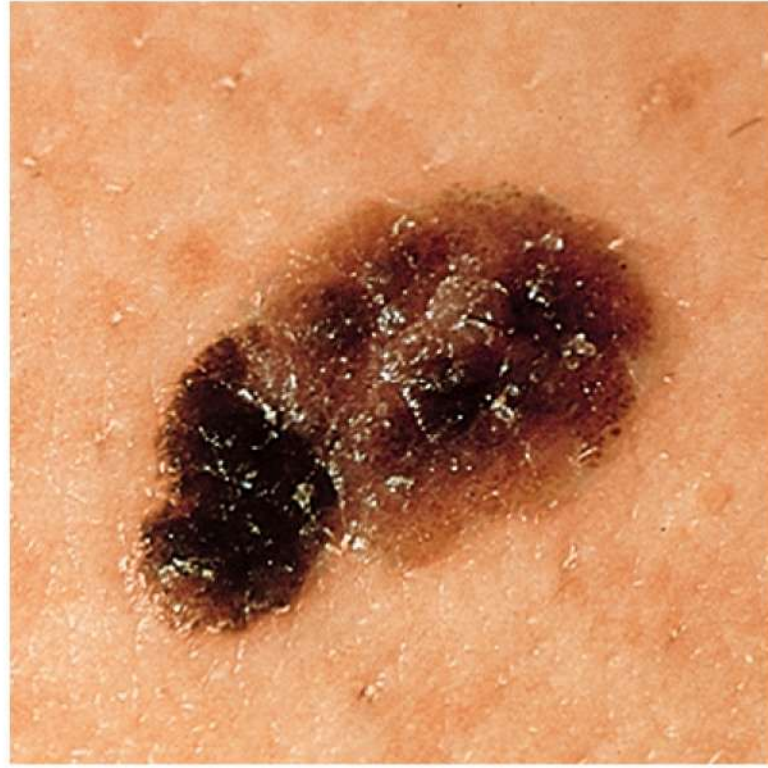



(h) At birth

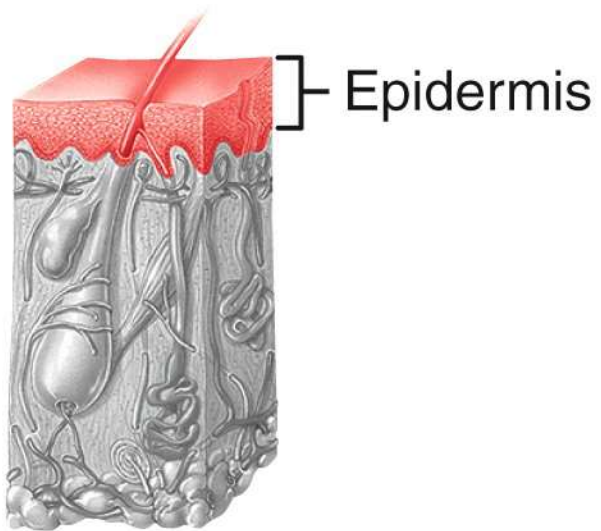
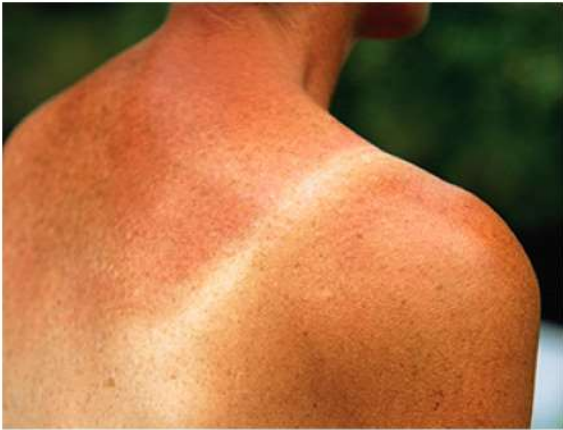

(a) Normal nevus (mole)



(b) Malignant melanoma

Sheila Terry/Science Photo Library/
Photo Researchers, Inc.



(a) First-degree burn
(sunburn)

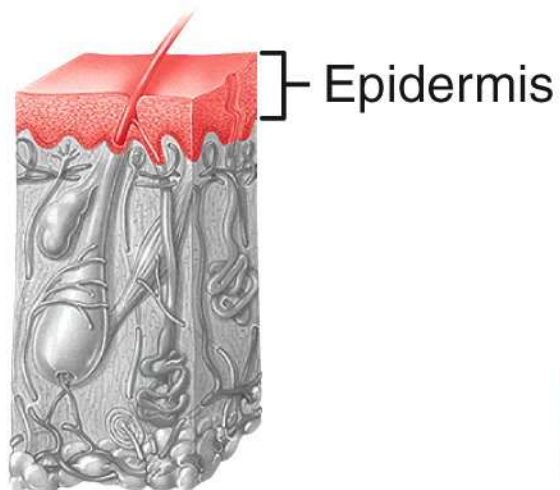
Sheila Terry/Science Photo Library/
Photo Researchers, Inc.



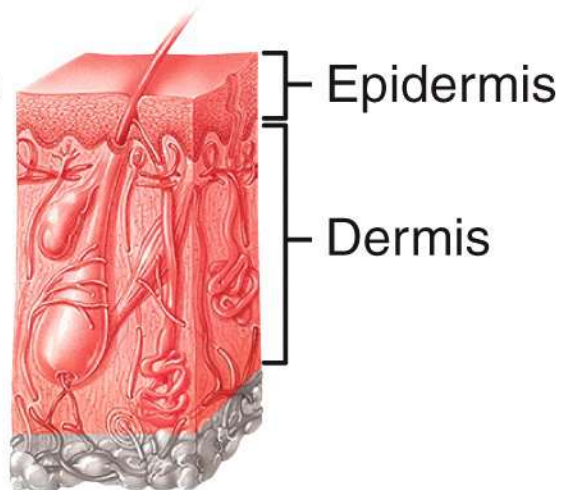
St. Stephen's Hospital/Science Photo
Library/Photo Researchers, Inc.



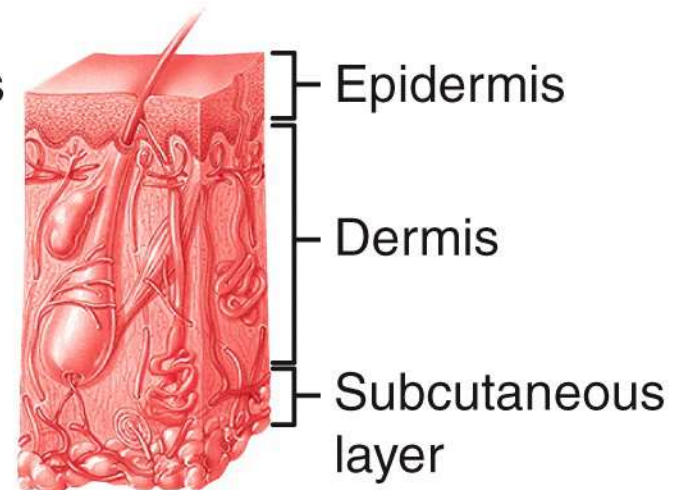
St. Stephen's Hospital/Science Photo
Library/Photo Researchers, Inc.



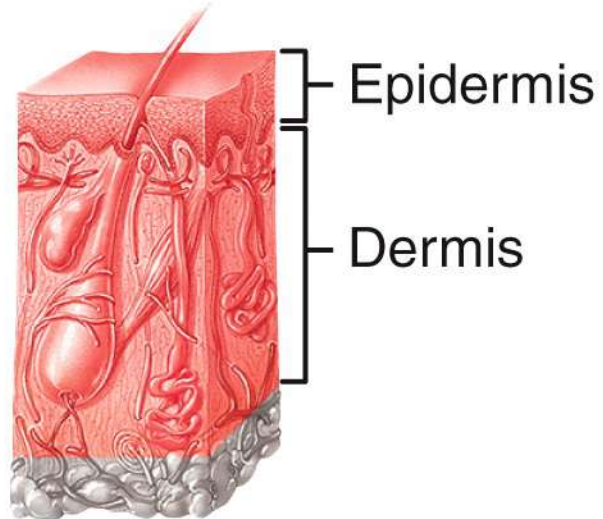
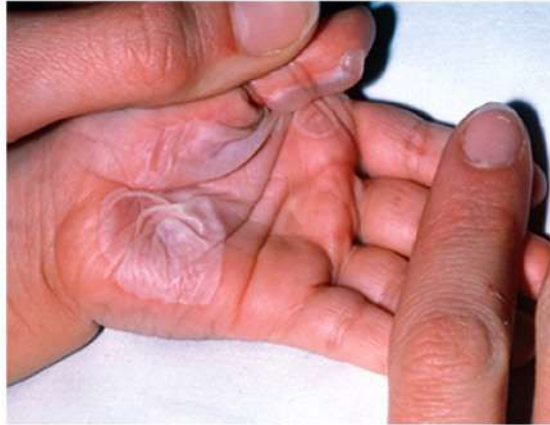(a) First-degree burn
(sunburn)



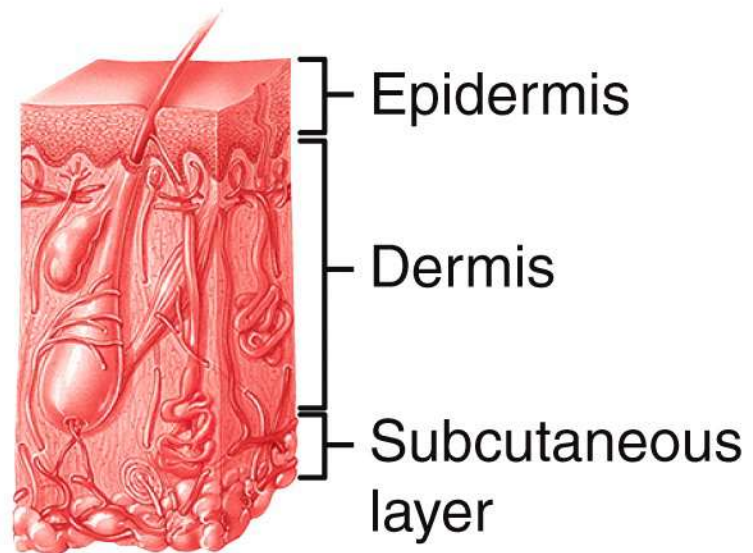
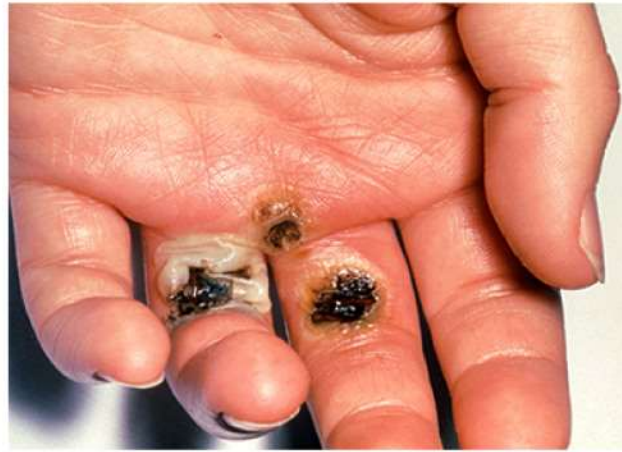(b) Second-degree burn
(note the blisters in
the photograph)



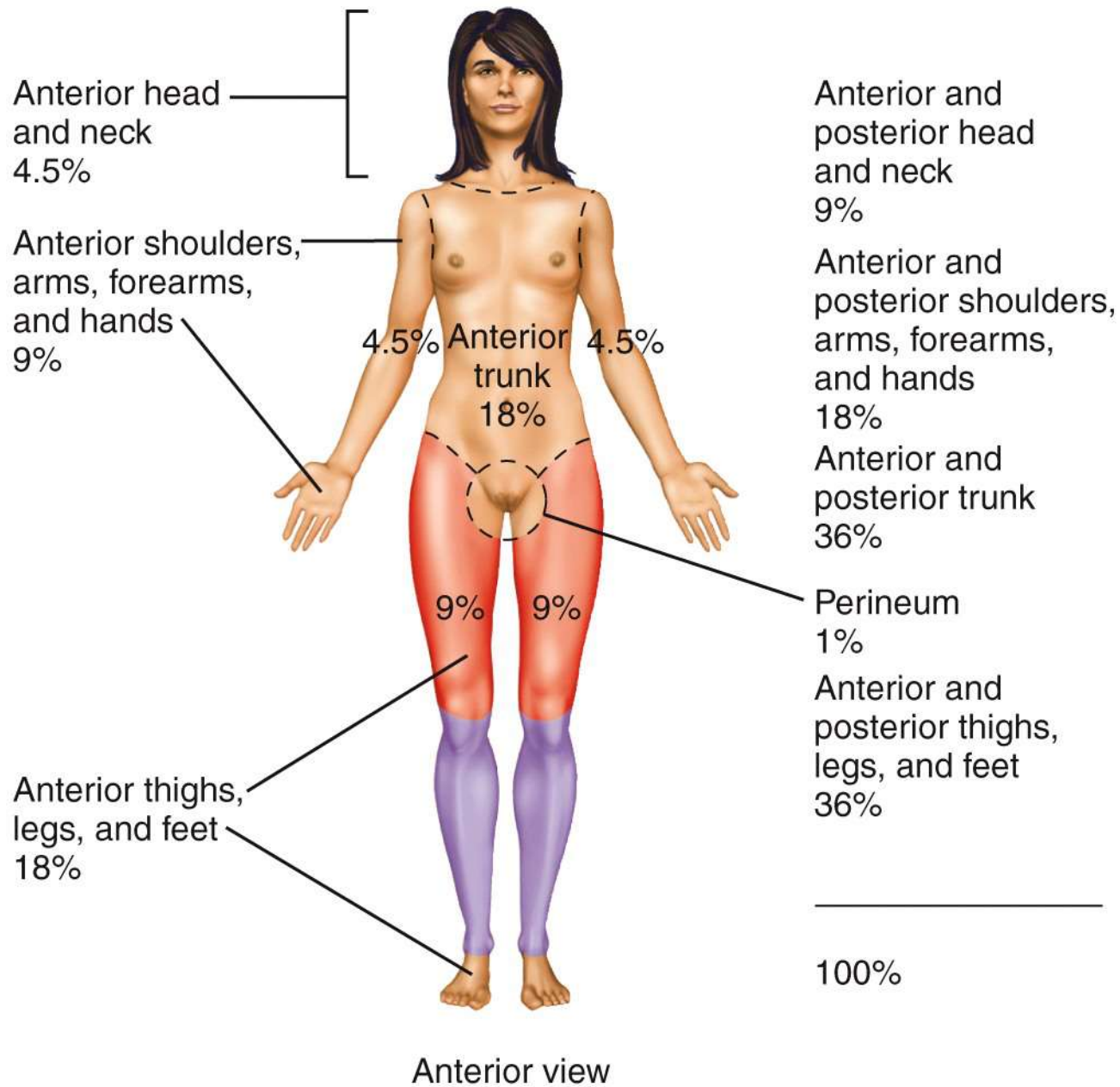
(c) Third-degree burn

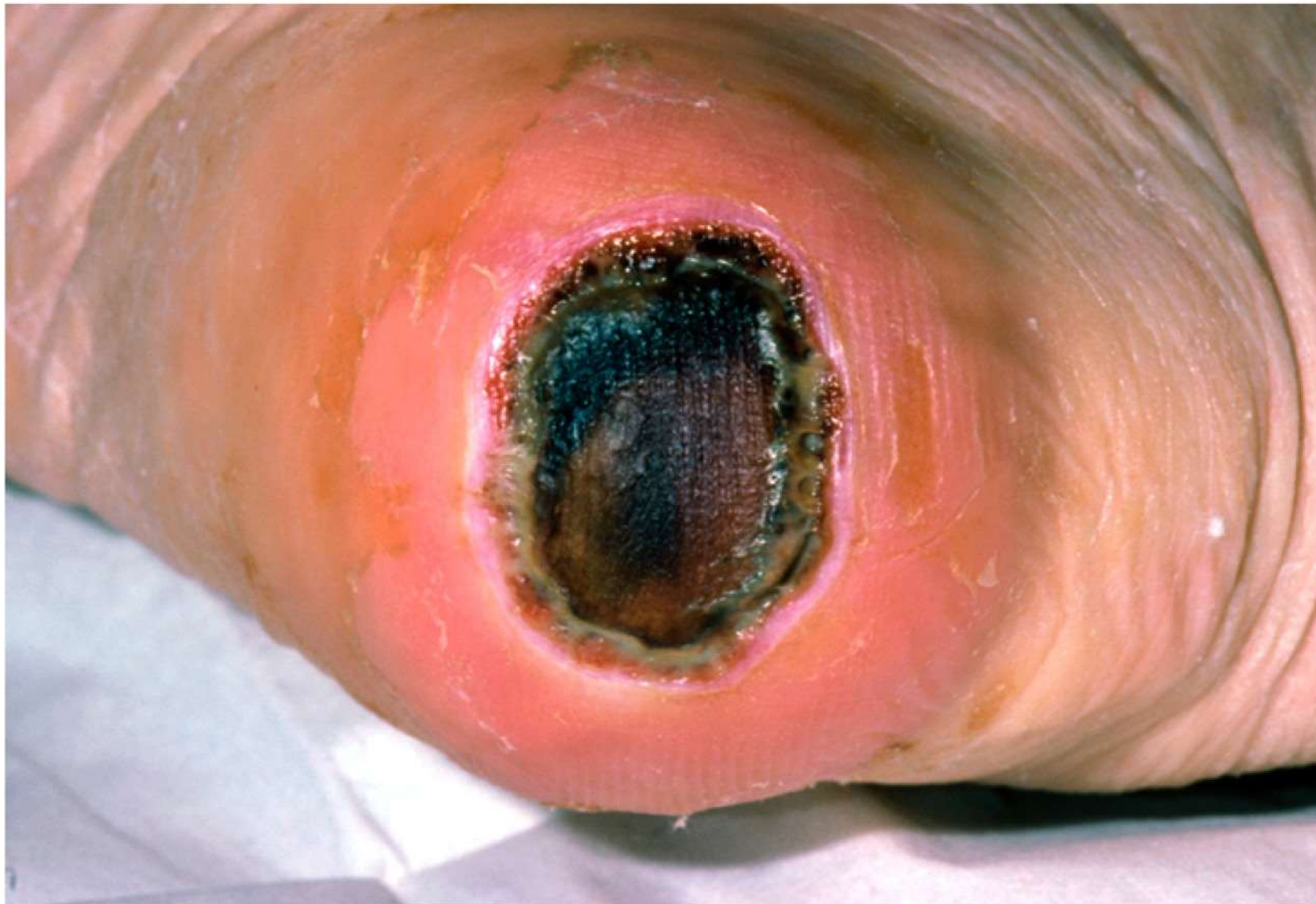

(b) Second-degree burn (note the blisters in the photograph)



(c) Third-degree burn





Dr. P. Marazzi/Science Photo Library/Photo Researchers, Inc.

Pressure ulcer on heel



Alberto E. Rodriguez/ Getty Images